

See discussions, stats, and author profiles for this publication at: <https://www.researchgate.net/publication/266344900>

# PSORIASIS AND HOMEOPATHY

Article · September 2011

---

CITATIONS

12

READS

9,469

1 author:



[Lawrence Chukwudi Nwabudike](#)

National Institute of Diabetes, Nutrition and Metabolic Diseases, N.C. Paulescu

57 PUBLICATIONS 188 CITATIONS

[SEE PROFILE](#)

Some of the authors of this publication are also working on these related projects:



Foot Ulcer Research [View project](#)



Clinical Dermatology [View project](#)

## PSORIASIS AND HOMEOPATHY

L.C. NWABUDIKE<sup>1</sup>

<sup>1</sup>National Institute of Diabetes, Nutrition and Metabolic Diseases "N.C. Paulescu", Romania  
Corresponding author: L.C. Nwabudike, E-mail: chukwudi.nwabudike@live.com

Received September 08, 2011

Psoriasis is an inflammatory skin disorder which may affect the skin, nails and joints. It is fairly common and affects individuals of all ages. It frequently manifests in the skin overlying the joint, elbow and lumbosacral areas. Lesions may be brought on by trauma also (the Koebner phenomenon). There are periods of quiescence of varying length, when the disease is in apparent remission and periods of flare. Psoriasis is associated with a number of comorbid conditions such as cardiovascular disease, uncomplicated diabetes, hepatitis B and C, renal failure, asthma and peptic ulcers. A number of treatment modalities exist for psoriasis, including topical and systemic treatments and new modalities continue to appear, all with varying effects and also with risks of complications. Four cases of psoriasis (generalised, scalp and nail involvement) treated homeopathically are presented.

*Key words:* psoriasis; inflammatory skin disorder; stress responders.

### INTRODUCTION

Psoriasis is an inflammatory skin disorder with a world-wide frequency of about 2-3% of the general population<sup>1,3</sup>. It is associated with a number of comorbid conditions, including cardiovascular disease, uncomplicated diabetes, hepatitis B and C, renal failure, asthma and peptic ulcers<sup>2</sup>. Emotional stress is considered an important factor and 37-78% of patients believe that stress affects their condition<sup>3</sup>. Generally, people that suffer from dermatoses can be divided into "stress responders", who believe that stress affects their disorder and "non-stress responders", who see no association between their disease and emotional stress. Systemic therapies, including cytotoxic agents, retinoids and biologicals<sup>4</sup>, as well as topical therapies such as vitamin D analogues, topical calcineurin inhibitors, topical steroids, anthralin and topical retinoids<sup>5</sup> are used in psoriasis, with varying effect. Homeopathy is a system of treatment that utilises high dilutions of substances in an individualised manner to treat

disease. It depends predominantly on the psychological state of the individual patient to determine treatment. Four cases of psoriasis treated with homeopathy are presented. Perhaps, one day, this system of treatment will be considered a useful option in the therapy of psoriasis.

### Case presentations

*First case* - A 14-year old male patient, accompanied by his mother, presented with a skin eruption localised to the scalp and ear areas, which began 11 years before. It began in the area of the left ear, waxed and waned, then remained stable in the 1 year preceding presentation. It appeared on the scalp about 1 month before presentation. He had received topical steroids with temporary relief. His past medical history was insignificant, with the exception of a known penicillin allergy.

On examination, an erythematous, well-defined plaque, covered with squames could be seen in the left preauricular area. Thick, whitish squames

covering the central scalp could be observed. General examination yielded nothing significant.

The patient initially received the homeopathic medicine *Lycopodium* at C200 potency, to be administered weekly and a bland hydrating cream. Follow-up three weeks later showed an aggravation of the lesions with fissuring in the area of the left lobe, which worried his mother. His prescription was changed to *Lachesis* at C200 potency, also administered weekly. He began to show improvement at 1 and 2 weeks post-treatment, by 2 months following *Lachesis*, the patient was already almost lesion-free in the scalp area and much improved in the preauricular area. At 4 months post-treatment both scalp and periauricular lesions were almost gone. He appeared to show a mild resurgence of scalp lesions at 5 months after onset of *Lachesis*. He was asked to repeat the treatment and reports from his mother continue to indicate that he is lesion-free. He remains lesion-free and has not returned for follow-up.

*Second Case* - A 66-year old male patient presented with a three-month history of a generalised eruption following the news of accidental poisoning of his daughter. The lesions were occasionally itchy. His past medical history was not significant except for mild hypertension for which he received no treatment.

Physical examination showed well-defined, erythematous plaques, covered with squames, with a generalised distribution as well as scalp involvement. General examination was not significant.

He received the homeopathic remedy *Sulphur* at M potency with weekly administration and a sulphur-based cosmetic cream for his itching. At his follow-up visits at 1 and 2 months, he showed marked improvement and, at 4 months, he showed almost complete clearing. He is still-lesion free 2 years after cessation of treatment, with the exception of a few mild erythematous lesions in his elbow areas.

*Third Case* - A 42-year old male patient presented with a 10-year history of a generalised skin eruption also involving the scalp area that responded variably to topical and systemic therapies. His past medical history was not significant.

Physical examination revealed a healthy male, with generalised, well-defined, erythematous plaques, partially covered with thick squames, as well as diffuse, erythematous and squamous

lesions on the scalp. He received the homeopathic remedy *Lachesis* at M potency. His general state improved, in spite of an aggravation of his lesions at his one-month follow-up. For financial reasons – the patient resides in another city – he did not return but reported an amelioration of his lesions with photos sent by email. He continues to remain lesion-free, with the exception of occasional mild, transitory recrudescences at the onset of winter.

*Fourth Case* - A 29-year old female patient presented with a history of nail disease and skin eruptions of 1 year duration. The nail disease comprised small, fluid-filled, periungual lesions and thickened, discoloured nails. These had been preceded by palmar, squamous lesions. She had been diagnosed with psoriasis and treated with topical steroids. Her past medical history included an appendectomy at 12 years of age, left facial palsy 3 months before onset of psoriasis, duodenal ulcer and left femoral hernia, 3 months after the onset of psoriasis.

On examination, yellowish nail discolouration, thickening and dystrophy could be seen on some finger and toe nails. There was accompanying periungual squamation.

Mycology showed rare fungal hyphae. She received the homeopathic remedy *Arsenicum album* at M potency, weekly and a 10% urea cream, which was to be applied around the nails. At 6 weeks, she had observed substantial improvement in her general state and felt able to resume many activities, although she showed a mild aggravation of her palmar lesions. Subsequent visits showed amelioration of these lesions and nail growth. She reported pregnancy (6 weeks gestation) at 5 months after treatment, with nail growth and improvement of her periungual lesions, although she had ceased treatment 2 weeks earlier.

The patient was still dissatisfied and her treatment was changed to the homeopathic medicine *Lycopodium* at M potency. She returned 9 months later and her nail lesions were gone, with the exception of the nail of her right ring finger, which, though diminished, was still not completely healed.

## RESULTS AND DISCUSSION

Psoriasis is an inflammatory disease affecting about 2-3% of the world population<sup>1,3</sup>. Various factors have been implicated, including stress<sup>3</sup>, prior streptococcal infection<sup>6</sup>, interleukin 17

upgrade<sup>7</sup> and, most recently, a candidate gene appears to have been identified<sup>8</sup>.

Systemic therapies, including cytotoxic agents, retinoids and biologicals<sup>4</sup>, as well as topical

therapies such as vitamin D analogues, topical calcineurin inhibitors, topical steroids, anthralin and topical retinoids<sup>5</sup> have all been utilised, with varying results.



Fig. 1. First case - scalp - before treatment (a).

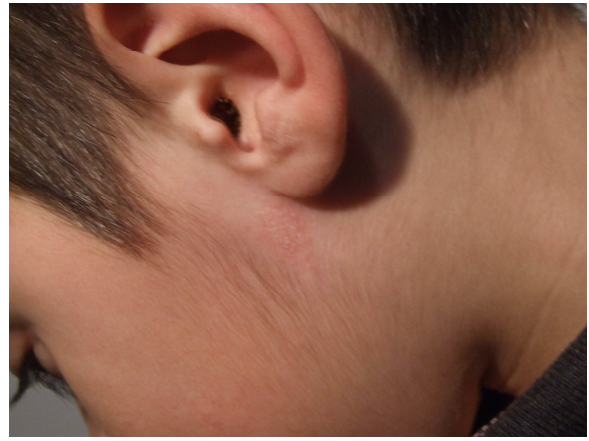

Fig. 2. First case - before treatment (b).

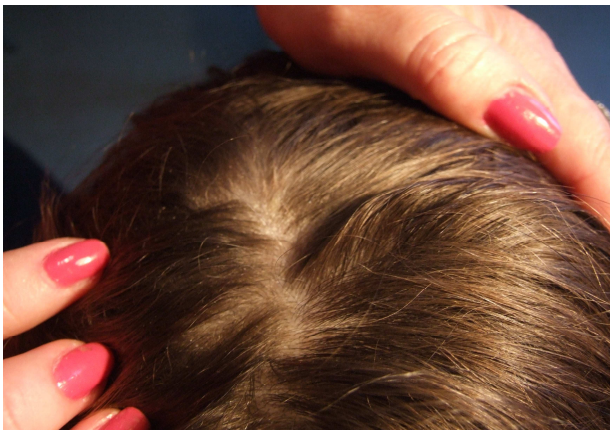

Fig. 3. First case - scalp - after treatment (a)

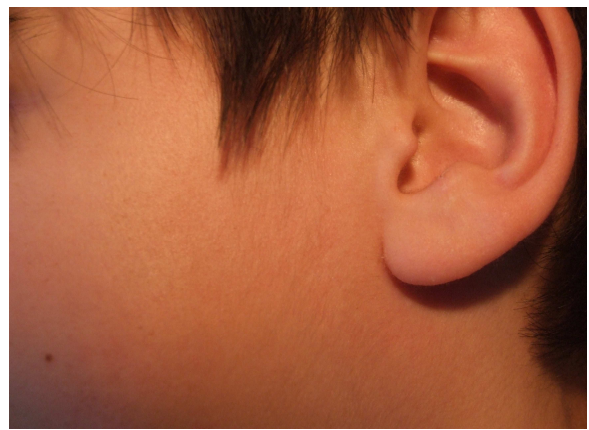

Fig. 4. First case - preauricular area - after treatment (b)

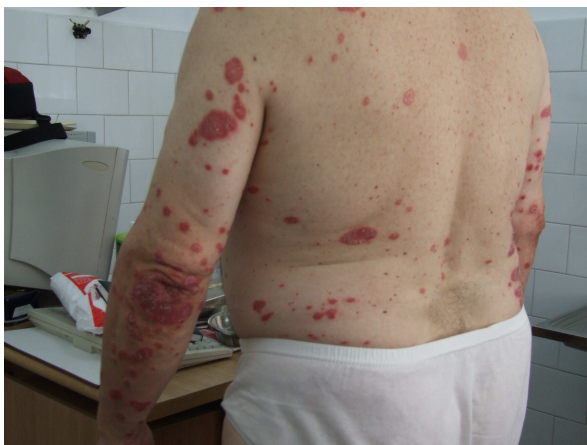

Fig. 5. Second Case - A 66-year old male - before treatment (a).

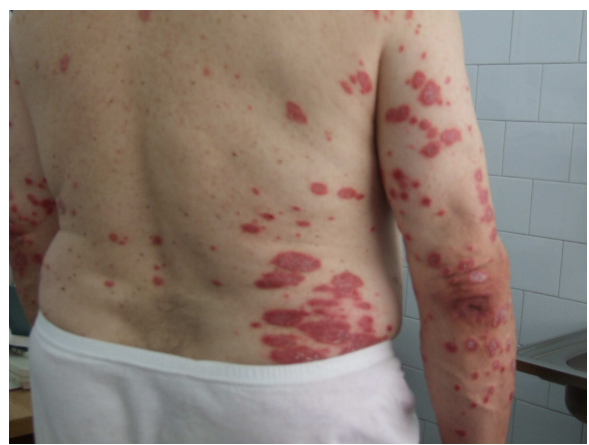

Fig. 6. Second Case - A 66-year old male - before treatment (b).

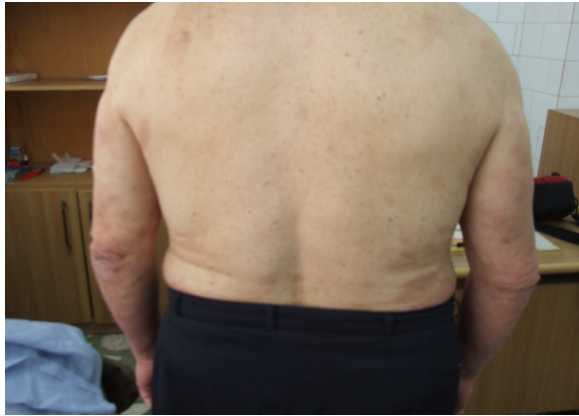

Fig. 7. Second Case - at 2 years post-treatment.

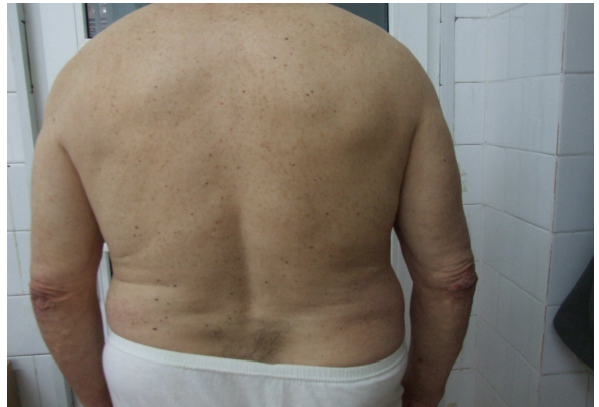

Fig. 8. Second Case - at 5 months post-treatment.

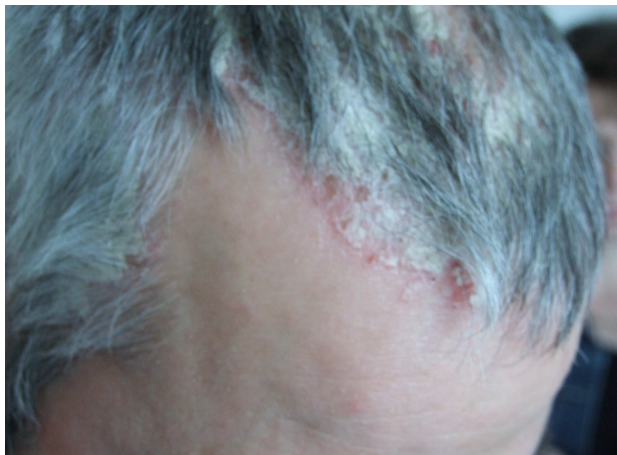

Fig. 9. Third case - scalp area - before treatment.

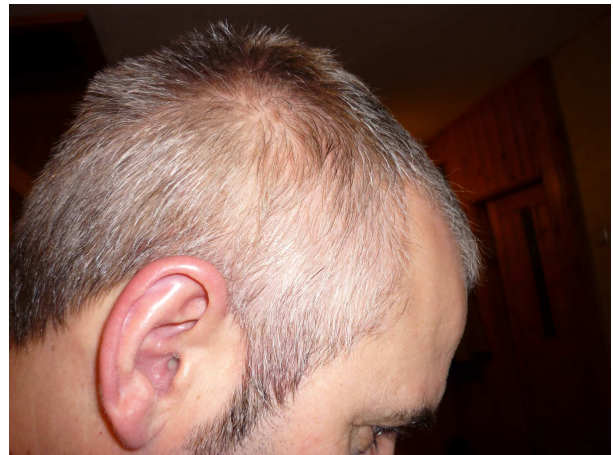


Fig. 10. Third case - scalp area - after treatment.

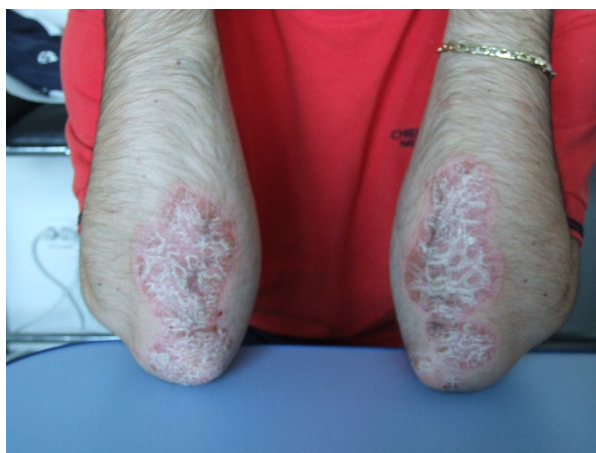

Fig. 11. Third case-elbow area- before treatment.

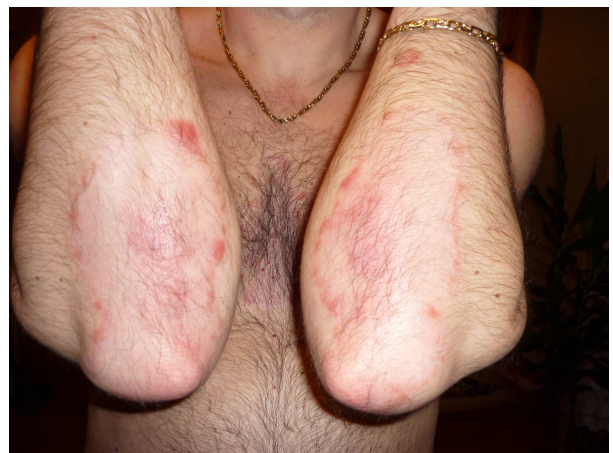

Fig. 12. Third case-elbow area- after treatment.

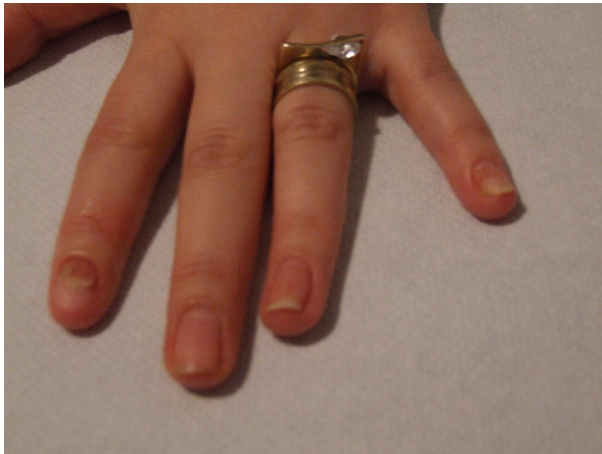

Fig. 13. Fourth case - left finger nails - before treatment.

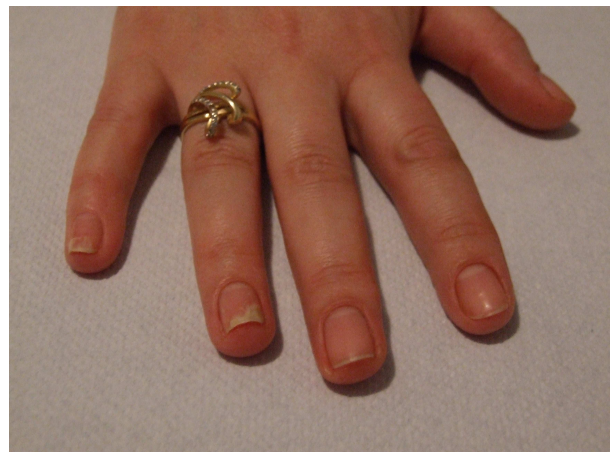

Fig. 14. Fourth case - right finger nails - before treatment.

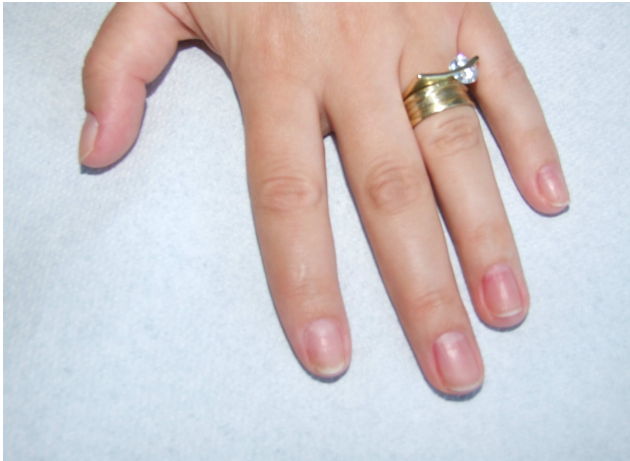

Fig. 15. Fourth case - left fingernails - after treatment.

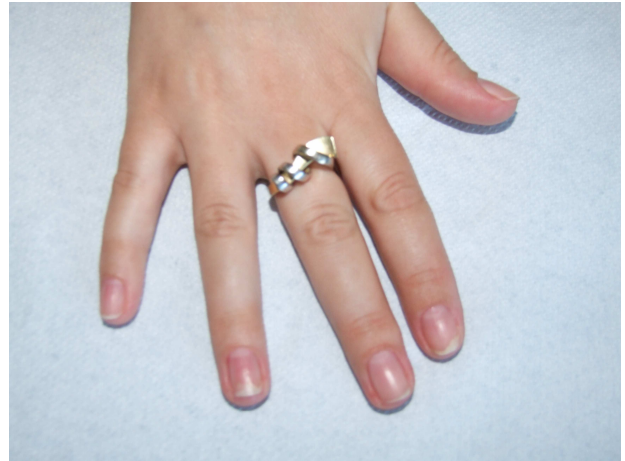

Fig. 16. Fourth case - right fingernails - after treatment

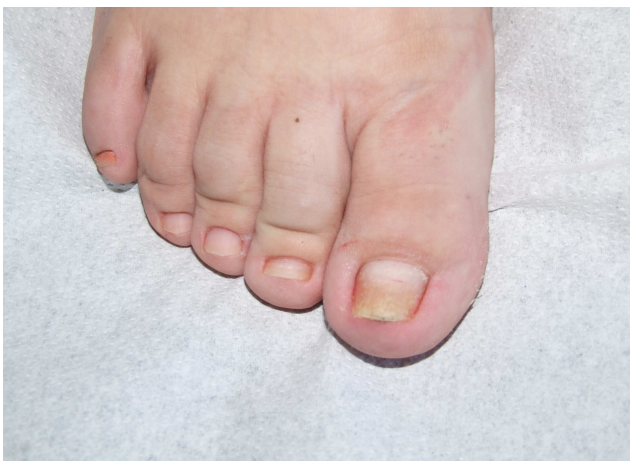

Fig. 17. Fourth case - toe nail - after treatment.

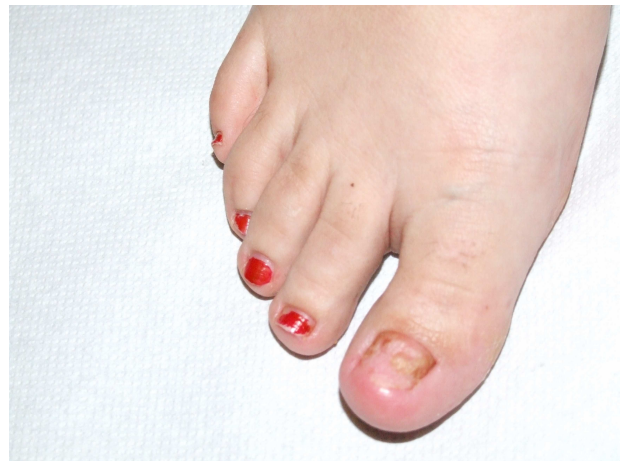

Fig. 18. Fourth case - toe nail - before treatment.

Stress is an important trigger factor in 37-78% of patients<sup>3</sup>. In this paper, 4 cases of psoriasis treated homeopathically are presented. Homeopathy is an individualised form of holistic medicine that relies on emotional factors for treatment selection, if the best effect is to be achieved. One case suffered nail psoriasis, while the remaining three cases suffered scalp and body psoriasis of different degrees of severity. Although only affecting the nails, nail psoriasis can be associated with an increased impact on health-related quality of life, as well as increased severity of joint and skin disease and pain<sup>9</sup>. The patients' pre-treatment duration of disease varied, all had received standard topical and, in some cases, systemic treatment, with the exception of case 2. Increasingly, complementary medical methods are gaining popularity amongst the general populace. Some estimates have put the out of pocket spending of patients on complementary and alternative medicine (CAM) methods to be about GB£450 in the UK and US\$27-34 billion in the US<sup>10</sup>. With such economic figures, it is no surprise that increasing debate over the role of CAM in health care delivery is occurring. Governments are increasingly considering the inclusion of CAM in public health care subsidies and this is likely to further fuel the ongoing debate. Homeopathy is an outpatient system of care and patients with psoriasis have been found to prefer outpatient care for their disorder, even at the risk of increased side-effects of therapy and increased costs<sup>11</sup>. We have published other anecdotal accounts of dermatoses treated homeopathically<sup>12,13</sup> and hope that the increasing numbers of similar reports would stimulate further, more detailed, research into this burgeoning field.

### CONCLUSIONS

Psoriasis is a disorder in which up to 78% of cases have a strong underlying stress connection. Homeopathy relies chiefly on the individual personality traits of the patient to make a diagnosis and treat. It would therefore appear that psoriasis is suited to a majority of cases treated by homeopathy. The cases presented received individualised remedies. A case of scalp and a case of nail psoriasis appeared to benefit from the

same remedy, which underscores the need for individualisation, rather than a focus on the physical pathology, when one approaches a case homeopathically. Homeopathy is predominantly an outpatient method of treatment, which fits with the preference of patients for treatment modalities that cause minimal disruption to their personal and professional lives<sup>11</sup>. Research needs to be done into the role homeopathy may play in the therapy of this disorder, as this may open up the possibility to another treatment modality and it is hoped that this paper will be a step towards this.

### REFERENCES

1. Meffert J. Psoriasis Medscape CME <http://emedicine.medscape.com/article/1943419-overview>.
2. Yang Y-W, Keller JJ, Lin H-C. Medical Comorbidity Associated With Psoriasis in Adults. A population-based study. *BMJ* 2011; 165(5):1037-1043.
3. Heller MM, Lee SE, Koo YMJ. Stress as an influencing factor in psoriasis. *Skin Therapy Letter* 2011; 16(5).
4. Lee M, Kalb RE. Systemic Therapies for Psoriasis. *Dermatology Nursing* 2008; 20(2):105-111.
5. Kurian A, Barankin B. Current Effective Topical Therapies in the Management of Psoriasis. *Skin Therapy Letter* 2011; 16(1):4-5.
6. McFadden JP, Baker BS, Powles AV, Fry L. Psoriasis and Streptococci: The Natural Selection of Psoriasis Revisited. *BMJ* 2009 160(5):929-937.
7. van Beelen JA, Teunissen M, Kapsenberg MI, de Jong CE. Interleukin-17 in Inflammatory Skin Disorders. *Curr Opin Allergy Clin Immunol*. 2007; 7(5):374-381.
8. Tsai KY. A Psoriasis Gene Emerges. IL-36-Receptor Antagonist Causes Generalised Pustular Psoriasis. *Journal Watch on Medscape* <http://www.medscape.com/viewarticle/749283>.
9. Reich A, Szepietowski JC. Quality of Life in Patients With Nail Disorders. *Medscape News* [http://www.medscape.com/viewarticle/753711\\_3](http://www.medscape.com/viewarticle/753711_3).
10. Spinks J, Hollingsworth B. Are the Economics of Complementary and Alternative Medicine Different to Complementary Medicine? *Expert Revs Pharmacoeconomics Outcomes Res*. 2009; 9(1):1-4.
11. Schaarschmidt M-L, Schmieder A, Umar N, Terris D, Goebeler M, Goerdts S, Peitsch WK. Patient Preferences for Psoriasis Treatments. Process Characteristics can Outweigh Outcome Attributes. *Arch Dermatol*. 2011; 147(11):1285-1294.
12. Nwabudike LC. Homeopathy in the Treatment of *Verruca Vulgaris* – An Experience of Two Cases. *Proc. Rom. Acad. Series B*, 2010; 2:147-149.
13. Nwabudike LC. Homeopathy and Seborrheic Dermatitis. *Our Dermatol. Online*. 2011; 2(4): 208-210.